

Occurrence of spargana infection in *Dermatonotus muelleri* Boettger, 1885 (Anura, Microhylidae) from a coastal complex in northeastern Brazil

Castiele Holanda Bezerra^{1*}, Roberta da Rocha Braga¹, Diva Maria Borges-Nojosa¹ and Gardel Almeida Silva¹

Sparganosis is a parasitic disease caused by tapeworm plerocercoid larvae of the order Pseudophyllidea (Rego and Schäffer, 1992). The cestoid life cycle is complex, involving more than one intermediate host. The adult stage inhabits the small intestines of domestic and feral carnivores. Proceroid larvae occur in copepods, while plerocercoid larvae, known as spargana, form cysts in the body cavities, tissues and organs of amphibians, reptiles and mammals that eat copepods or infected vertebrate hosts (Berger et al., 2009). Sparganosis in humans is a public health issue; it is well documented in China (Qiu and Qiu, 2009), and a few cases have been reported in Brazil (Fróes, 1967; Gomes et al., 1996; Mentz et al., 2011). Spargana have a cosmopolitan distribution and have been reported from reptiles and mammals as well as amphibians (Tandon and Imkongwapang, 1999; Berger et al., 2009; Gómez-Puerta et al., 2010), including Brazil (Mueller et al., 1975; Gutierrez et al., 1977; Rego and Schäffer, 1992). Here we report a spargana infection in *Dermatonotus muelleri* Boettger, 1885 (Anura, Microhylidae). The frog specimen was collected from the coastal complex of Pecém, municipality of São Gonçalo do Amarante, state of Ceará, northeastern Brazil (3°33'S; 38°49'W). The specimen was taken to the Núcleo Regional de Ofiologia da UFC, euthanized by immersion in 5% ethanol, fixed in 10% formalin, and after necropsy deposited in the Herpetological Collection of the Universidade Federal do Ceará (CHUFC A 5811). The abdomen was opened by a mid-ventral incision, and 75 spargana that were encysted in the abdominal organs as well as free within the coelom were removed (Fig. 1). Tissue samples containing cysts were submitted to histopathologic analysis, although the

very thin mesothelium tissues were lost in the process. The remaining cysts were ellipsoid, whitish, with thick and matted walls, and the largest cyst measured 2.14 x 1.30 x 1.38 mm. Histological diagnosis revealed curled larvae, with a mean length of 2.31 mm and width of 0.24 mm (Fig. 2), with a flattened shape and transverse folds. It was not possible to analyze the larvae outside the cysts, because they were adhered to the cyst walls. This morphology is typical of plerocercoid larvae or spargana, similar to the genus *Spirometra*, found by Berger et al. (2009) in Australian tree frogs. In this study, the most prevalent sites of infection were subcutaneous abdominal tissues. Berger et al. (2009) mentioned as the most prevalent sites the hindlimb muscle bundles, especially the thighs, but found several spargana in other tissues, such as those in this study, as well as other kinds of muscles and the coelomic cavity. Intensities of infections reported by Tandon and Imkongwapang (1999), Berger et al. (2009) and Liu et al. (2010) were 18, 16 and 15 spargana respectively. In China, spargana infection in frogs is well documented. Mao et al. (2009) reported the most intense infection, recovering 131 larvae. Therefore, the intensity of more than 70 spargana collected in the present study can be considered a moderate infection. The occurrence of spargana in amphibian hosts is little known in Brazil, but is frequently reported in Asian countries. *Dermatonotus muelleri* is also little studied, so reports of its parasite ecology are important for improving understanding of its natural history.

¹ Núcleo Regional de Ofiologia, Qd. 905, Campus do Pici, Universidade Federal do Ceará, Av. Mister Hull, S/N, 60.455-760, Fortaleza-CE, Brazil.

*Corresponding author; email: castieleholanda@gmail.com

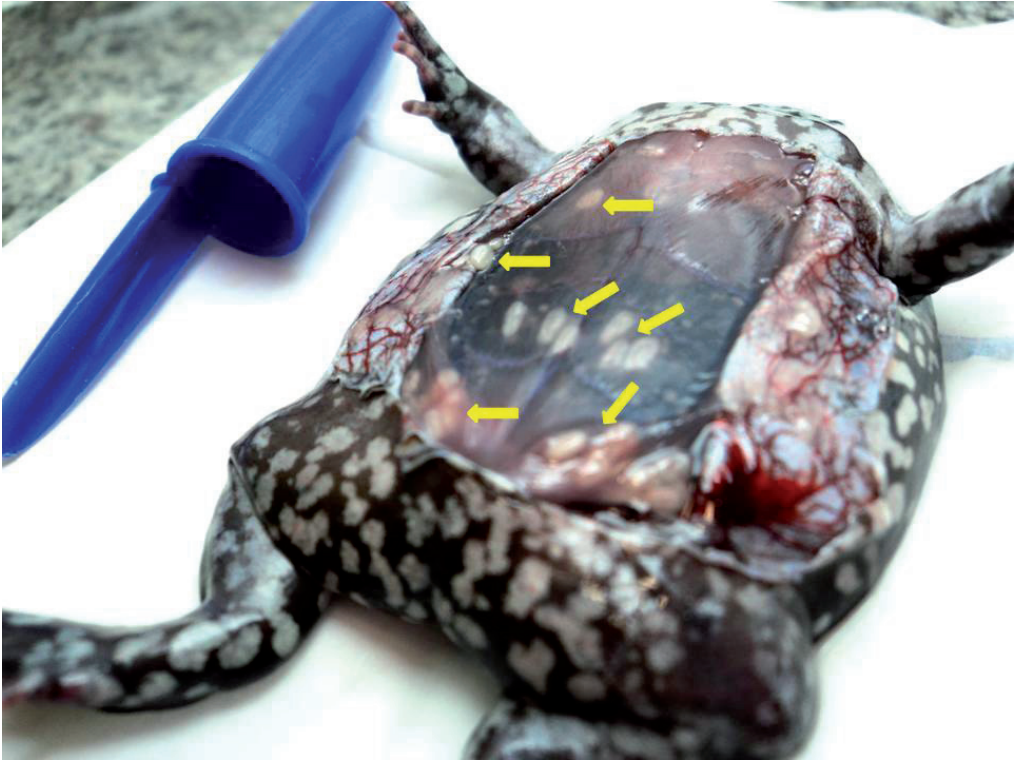


Figure 1. *Dermatonotus muelleri* with encysted spargana (arrows). Photo: R. R. Braga.

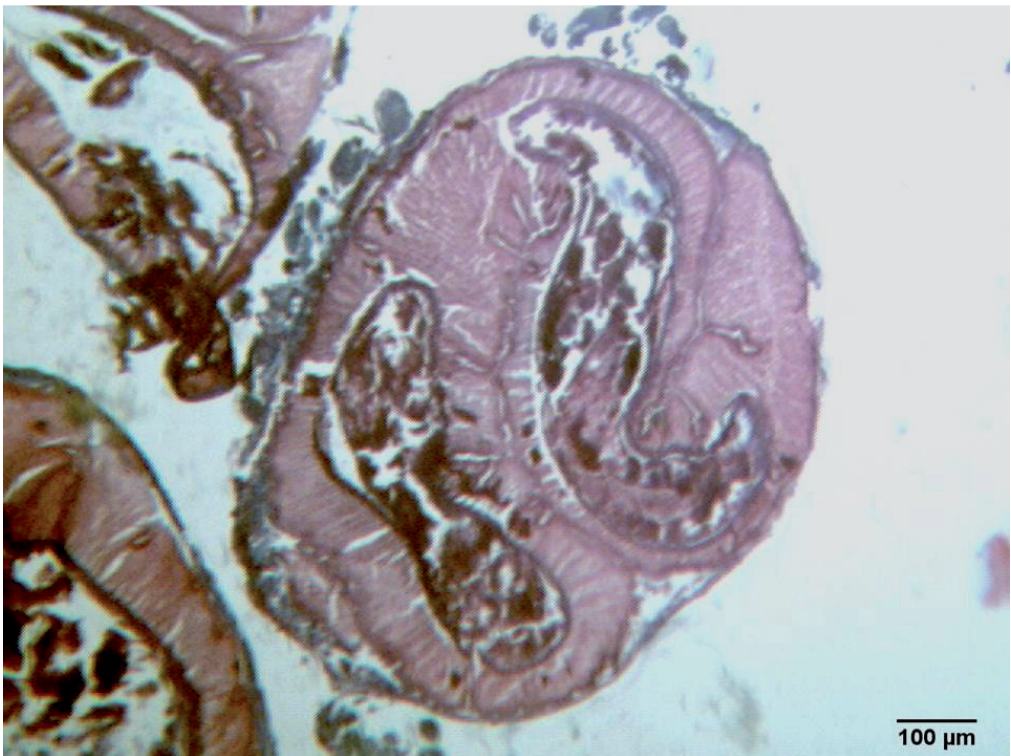


Figure 2. Histoanatomy of the spargana with coiled, encysted larvae. Photo: R. R. Braga.

References

- Berger L., Skerratt, L.F., Zhu, X.Q. Young, S., Speare, R. (2009): Severe sparganosis in Australian tree frogs. *J. Wildl. Diseases* **45**(4): 921-929.
- Bowman, D.D., Hendrix, C. M., Lindsay, D.S., Barr, S. C. (2002): The Cestodes: With Notes on the Few Acanthocephala Reported from Cats: *Spirometra* Species. In: *Feline Clinical Parasitology*, p. 189-194. Iowa State University Press, Ames.
- Fróes, O.M. (1967): Esparganose humana: o primeiro caso relatado para o Brasil. In: *Anais de lo I Congreso Latinoamericano de Parasitología*, p. 143. Santiago, Chile.
- Gomes, A.H.S., Cacciaccaro, E.N., Mangini, A.C.S., Dias, R.M.D.S., Lapola, S.R., César, N.P.A. (1996): Esparganose humana: relato de um novo caso no estado de São Paulo. *Rev. Inst. Adolfo Lutz* **56**(2): 13-15.
- Gómez-Puerta, L. A., Chávez, G., Enciso, M. A., Mendoza, A. P. (2010): Infestación por esparganos en ranas del genero *Pristimantis* (Anura, Strabomantidae) del Perú. *Rev. Per. Biol.* **17**(2): 265-266.
- Gutierrez, V.C., Fróes, O.M., Amato, J.F.R. (1977): Identificação de um hospedeiro intermediário de *Spirometra mansonoides* Mueller, 1935 na área de Porto Alegre, Rio Grande do Sul, Brasil. *Rev. Bras. Biol.* **37**: 131-133.
- Liu, W., Zhao, G.H., Tan, M.Y., Zeng, D.L., Wang, K.Z., Yuan, Z.G., Lin, R.Q., Zhu, X.Q., Liu, Y. (2010): Survey of *Spirometra erinaceieuropaei* spargana infection in the frog *Rana nigromaculata* of the Hunan Province of China. *Vet. Paras.* **173**: 152-156.
- Mao, J.Z., Zhou, B.J., Wang, K.G., Wen, M. (2009): Investigation of spargana in frogs in Huaxi area. *Chin. J. Paras. Parasitic Diseases* **27** (1):187-8.
- Mentz, M.B., Procianoy, F., Maestri, M.K., Rott, M.B. (2011): Case report: human ocular sparganosis in southern Brazil. *Rev. Inst. Med. Trop. de São Paulo* **53**(1): 51-53.
- Mueller, J.F., Fróes, O.M., Fernández, T. (1975): On the occurrence of *Spirometra mansonoides* in South America. *J. Paras.* **61**: 774-775.
- Qiu, M.H., Qiu, M.D. (2009): Human plerocercoidosis and sparganosis: I. A historical review on aetiology. *Chin. J. Paras. Parasitic Diseases* **27**(1): 54-60.
- Rego A.A., Schäffer, G.V. (1992): *Sparganum* in some Brazilian vertebrates: Problems in the identification of species of *Luheella* (*Spirometra*). *Mem. Inst. Oswaldo Cruz* **87**(1): 213-216.
- Tandon, V., Imkongwapang, R. (1999): Natural infection of *Sparganum* in frogs in Nagaland (Northeastern India) - an Amphibia-borne zoonosis? *Zoo's Print Journal* **14**(5): 13-16.